



Rhinoplasty

Double-Blind Comparison of Ultrasonic and Conventional Osteotomy in Terms of Early Postoperative Edema and Ecchymosis

A. Emre Ilhan, MD; Betül Cengiz, MD; and Basak Caypinar Eser, MD

Aesthetic Surgery Journal
2016, 1–12
© 2016 The American Society for
Aesthetic Plastic Surgery, Inc.
Reprints and permission:
journals.permissions@oup.com
DOI: 10.1093/asj/sjv260
www.aestheticsurgeryjournal.com
OXFORD
UNIVERSITY PRESS

Abstract

Background: Edema and ecchymosis are common complications of rhinoplasty. Modifications to osteotomy may reduce edema and ecchymosis and ameliorate postoperative discomfort in patients who undergo rhinoplasty.

Objectives: The authors performed osteotomy with conventional instruments or with an ultrasonic device and compared these methods with respect to the severities of ecchymosis and edema in the early postoperative period.

Methods: Fifty-six patients who underwent primary rhinoplasty with medial oblique, low-to-high internal osteotomy performed conventionally or with an ultrasonic device were evaluated in a prospective study. Photographs of the patients on postoperative days 3 and 7 were scored for ecchymosis and edema by 2 physicians who did not perform the operations and were blinded to the osteotomy procedure.

Results: Ecchymosis scores on postoperative days 3 and 7 and edema scores on postoperative day 3 were significantly higher for the 22 patients who underwent conventional osteotomy than for the 34 patients who underwent ultrasonic osteotomy, as scored by both examiners. Edema scores on postoperative day 7 were significantly higher for conventional than for ultrasonic osteotomy as assessed by 1 examiner but were not significantly different as determined by the other examiner.

Conclusions: The results of this comparative study suggest that rhinoplasty with ultrasonic osteotomy is associated with less edema and ecchymosis in the early postoperative period than is rhinoplasty with conventional osteotomy.

Level of Evidence: 3



Accepted for publication December 3, 2015.

The nose is a small but conspicuous organ, and any abnormality of the nose may cause a patient to seek surgical intervention. Moreover, rhinoplasty is regarded as the most challenging aesthetic surgical procedure of the face.^{1,2} The surgeon must successfully execute a series of steps to achieve the desired aesthetic and functional outcomes of rhinoplasty. Osteotomy is the final step in the creation of a sculpted bony pyramid and usually is the most difficult step in rhinoplasty, especially for the inexperienced surgeon. Visibility may be obstructed during osteotomy, and control over the incipient fracture line may not be possible. Owing to these challenges, osteotomy is associated with various unpredictable complications in the early postoperative period, such as bleeding, ecchymosis, and edema.

Several authors have compared osteotomy techniques and instruments with the aim of identifying an approach

that yields improved postoperative results and a reduced incidence of complications.²⁻⁶ However, each technique has unique advantages and disadvantages, and no accepted standard exists. Osteotomy causes soft-tissue injury, which yields prolonged edema and ecchymosis postoperatively. Moreover, osteotomy may cause bony irregularities of the lateral nasal wall and a comminuted fracture pattern, which may lead to poor aesthetic and functional outcomes,

Drs Ilhan, Cengiz, and Caypinar Eser are ear, nose, and throat surgeons in private practice in Istanbul, Turkey.

Corresponding Author:

Dr Basak Caypinar Eser, Rino Center, Erenköy, Bağdat Cad. Huzur Apt. No: 342/9 D:5, Kadıköy, İstanbul, Turkey.
E-mail: bskcypnr@hotmail.com

including nasal obstruction. These complications are especially apparent in patients with thin to normal skin.²⁻⁶ Therefore, osteotomy is crucial to the overall result of rhinoplasty.

In 1975, Horton et al^{7,8} introduced piezoelectric ultrasonic vibration for gentle cutting in alveolar bone surgery. These authors reported better healing of bony fragments with piezosurgery, and this technique was subsequently applied to various surgical fields.^{7,9} Piezoelectric technology was described for nasal osteotomy by Robiony et al¹⁰ in 2007 and by Pribitkin et al¹¹ in 2010. The piezosurgical device comprises a platform with a powerful piezoelectric hand piece and an irrigation system for cooling. Pribitkin et al¹¹ reported that the piezosurgical device permitted safe, precise, graded bone removal that was adjustable with respect to frequency and cutting power and that did not damage the surrounding soft tissue and mucosa of the nose. In this study, we compared the performance of ultrasonic osteotomy with conventional osteotomy with respect to the severities of ecchymosis and edema in the early postoperative period.

METHODS

Study Design and Patient Selection

Fifty-six patients who underwent primary rhinoplasty performed by the same surgeon (A.E.I.) in Istanbul, Turkey, from November 2014 to February 2015 were evaluated in a prospective study. This study was approved by the ethics committee of Medipol University (decision no. 331; June 25, 2015) and was conducted in accordance with the guidelines set forth in the Declaration of Helsinki. Preoperatively, all patients received detailed information about the study and provided written informed consent to undergo the operation and for their photographs to be published for educational purposes.

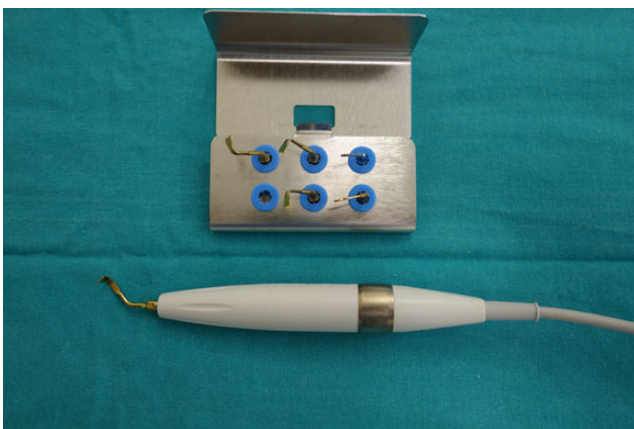


Figure 1. The ultrasonic device applied for osteotomy in this study.

Patients who presented for primary rhinoplasty were included. Excluded from the study were patients who were current smokers; patients with chronic rhinosinusitis, chronic dermatologic or rheumatologic diseases, nasal polyps, asthma, or allergic rhinitis; and patients who had previously undergone septoplasty or rhinoplasty. Detailed medical records were obtained for each patient, including bleeding diathesis. Patients were screened preoperatively for coagulation by evaluating prothrombin time, partial thromboplastin time, and bleeding/coagulation time. Patients with values outside reference ranges were excluded from the study.

Patients underwent rhinoplasty with osteotomy performed with an ultrasonic device or with conventional instruments. Ultrasonic osteotomy was carried out with a Variosurg3 piezosurgery unit (Nakanishi Inc, Tochigi, Japan) and customized cutting tips (Figure 1). Conventional osteotomy was conducted with a 4-mm straight osteotome and 4-mm guarded curved right and left osteotomes (all from Aesculap AG, Tuttlingen, Germany; Figure 2). Patients were randomly stratified by osteotomy procedure. Specifically, patients who underwent surgery during odd-numbered months received conventional osteotomy, and patients who underwent surgery during even-numbered months received ultrasonic osteotomy. Patients were not informed preoperatively regarding which osteotomy procedure they would undergo. All patients were advised to avoid aspirin derivatives, anti-inflammatory drugs, and analgesics for 7 days before the operation.

Surgical Techniques

All patients underwent open rhinoplasty. Propofol (2 mg/kg), remifentanyl (0.2 mg/kg/min), and rocuronium (0.6 mg/kg/min) were administered to induce anesthesia. Desflurane (4-6%) was administered as needed for maintenance

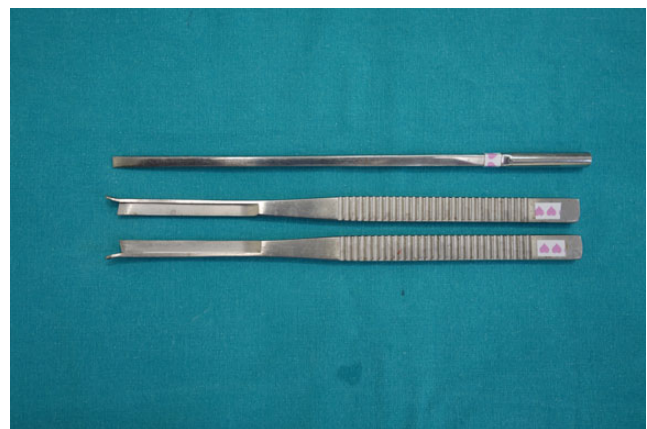

Figure 2. Conventional 4-mm osteotomes applied for osteotomy in this study.

of anesthesia. Sugammadex (2 mg/kg) was administered for reversal of anesthesia. Hypotensive anesthesia was applied to achieve an average arterial blood pressure of approximately 60 mm Hg. Lidocaine with 1:100,000 adrenaline was injected into the nasal dorsum and septum 10 minutes before the first incision was made.

A midcolumellar incision was made, and sharp dissection was performed to expose the nasal skeleton from the tip to the nasal bone. For patients who underwent ultrasonic osteotomy, a periosteal incision was made over the dorsum and nasal bone with a no. 15 scalpel blade, and the entire nasal bone was exposed subperiosteally by means of a periosteal elevator (Figure 3). For patients who underwent conventional osteotomy, subperiosteal elevation was limited to expose only the dorsum. Bleeding from perforating vessels was controlled with needlepoint cautery (90-degree angulation). All patients underwent hump resection with a Rubin osteotome followed by bone roof rasping, septoplasty (L-strut), and fixation of the caudal septum to the maxillary spine. Patients subsequently underwent medial oblique, low-to-high internal osteotomy with an ultrasonic device (Figure 4) or with an osteotome. The surgeon did not manually fracture the nasal bones; instead, the bones were carefully narrowed with the probe of the device. To prevent the bony vault from collapsing, the surgeon maintained the integrity of the inner mucosa, the transverse nasalis, and the scroll ligament. Following osteotomy, each patient underwent tip-plasty as needed (eg, tip sutures, repositioning of the lateral crura, or alar batten graft). Postoperatively, each patient received dexamethasone (8 mg). Patients received prophylactic antibiotic treatment during the first week postoperatively and were advised to apply a cold compress for 15 minutes every hour during the first 24 hours postoperatively. A video demonstrating the technique is available as Supplementary Material at www.aestheticsurgeryjournal.com.

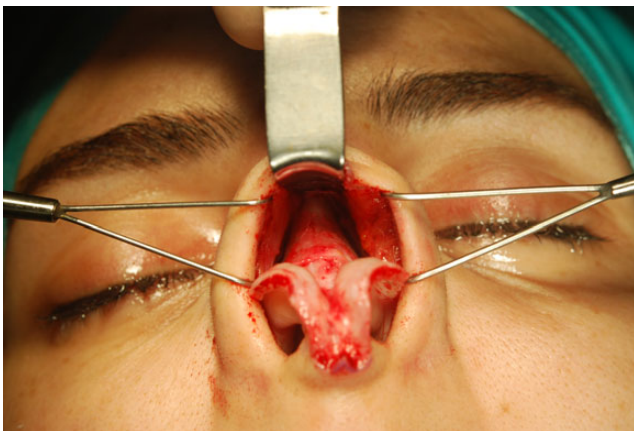


Figure 3. Intraoperative view of this 25-year-old woman who presented with functional (breathing) and aesthetic concerns. The patient underwent ultrasonic osteotomy.

Postoperative Evaluation

On postoperative days 3 and 7, patients were photographed by the author (A.E.I.) with a standard 60-mm lens and paraf-lash system (Nikon D80, Tokyo, Japan; and Macro Ring Flash MP-MRF32, Mcoplus, Shenzhen, China, respectively). The timing of the photographs was routine procedure at our clinic. The photographs were examined by 2 physicians who were blinded to the osteotomy procedure. These examiners scored the photographs with respect to the severities of ecchymosis and edema (Figures 5 and 6) and in comparison to preoperative photographs of these patients (Figures 7 and 8). The examiners were experienced specialists in otolaryngology, head and neck surgery, and facial plastic surgery and were not otherwise involved in the study. The edema and ecchymosis scoring system described by Kara and Gökalan¹² and adapted by Yucel¹³ was applied in this study (Figures 9 and 10).

Statistical Analyses

Statistical analyses were performed with NCSS 2007 software (Kaysville, UT). Descriptive statistics, including mean, standard deviation, median, frequency, percentage, minimum, and maximum, were calculated. The *t* test was applied for intergroup comparisons of normally distributed quantitative data. The Mann-Whitney U test was applied for parameters with non-normal distributions. Qualitative data were compared with Fisher's exact test. The intraclass correlation coefficient was computed to evaluate the compatibility of the 2 measurements. Changes within variables were ascertained by means of the Wilcoxon signed-rank test. Statistical significance was defined as $P < .05$.

RESULTS

At the beginning of the study, 76 patients were randomized by osteotomy procedure into 2 groups of 38 patients

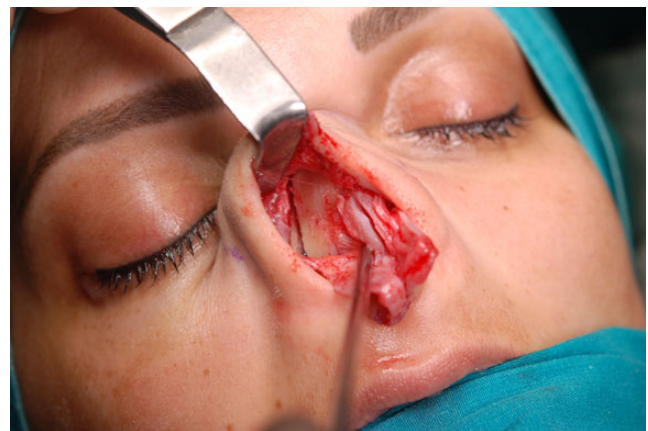

Figure 4. Intraoperative view of this 25-year-old woman (also presented in Figure 3) who underwent ultrasonic osteotomy.

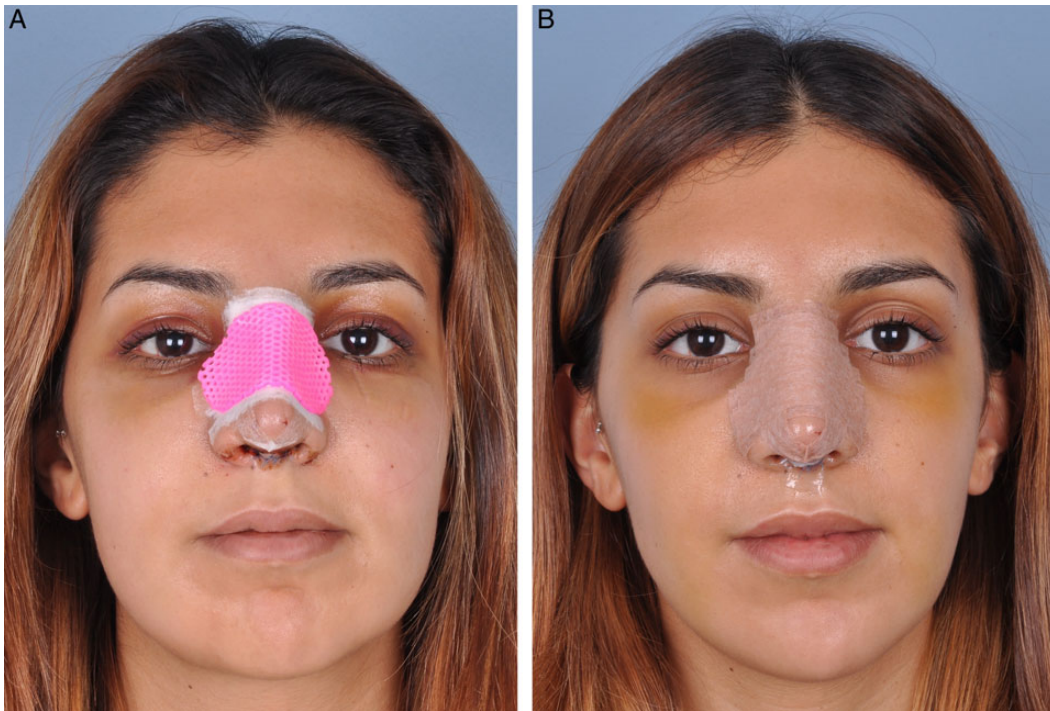


Figure 5. (A) Three- and (B) seven day-postoperative photographs of this 23-year-old woman who presented with functional (breathing) and aesthetic concerns and underwent conventional osteotomy.

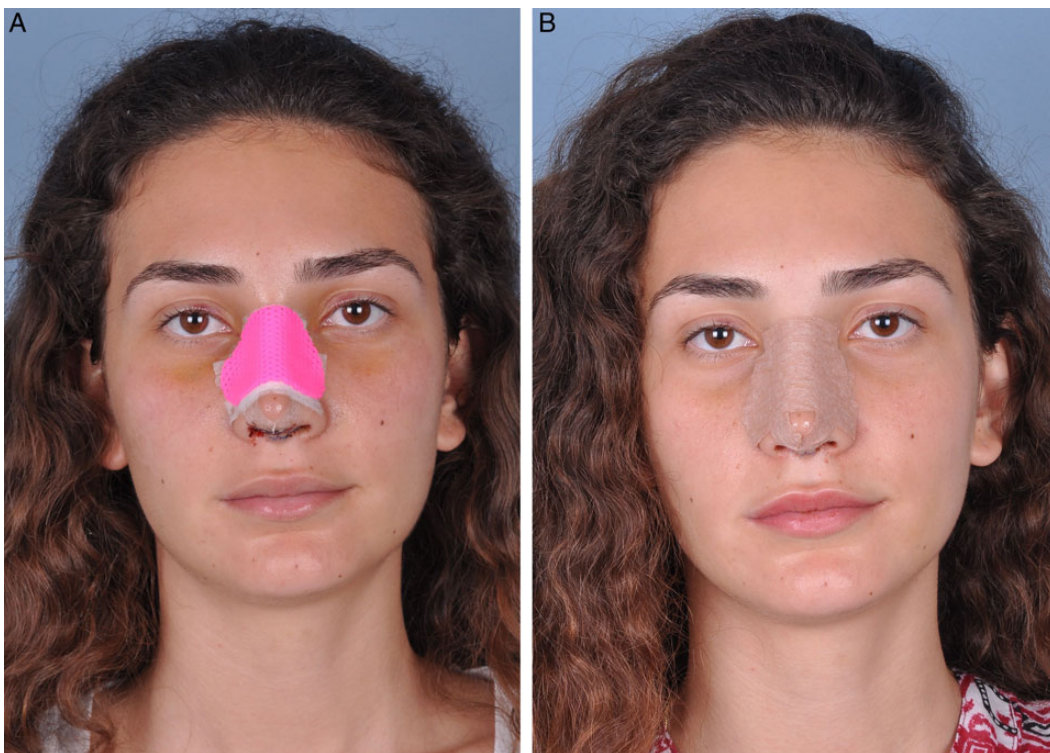

Figure 6. (A) Three- and (B) seven-day-postoperative photographs of this 25-year-old woman (also presented in Figures 3 and 4) who underwent ultrasonic osteotomy.

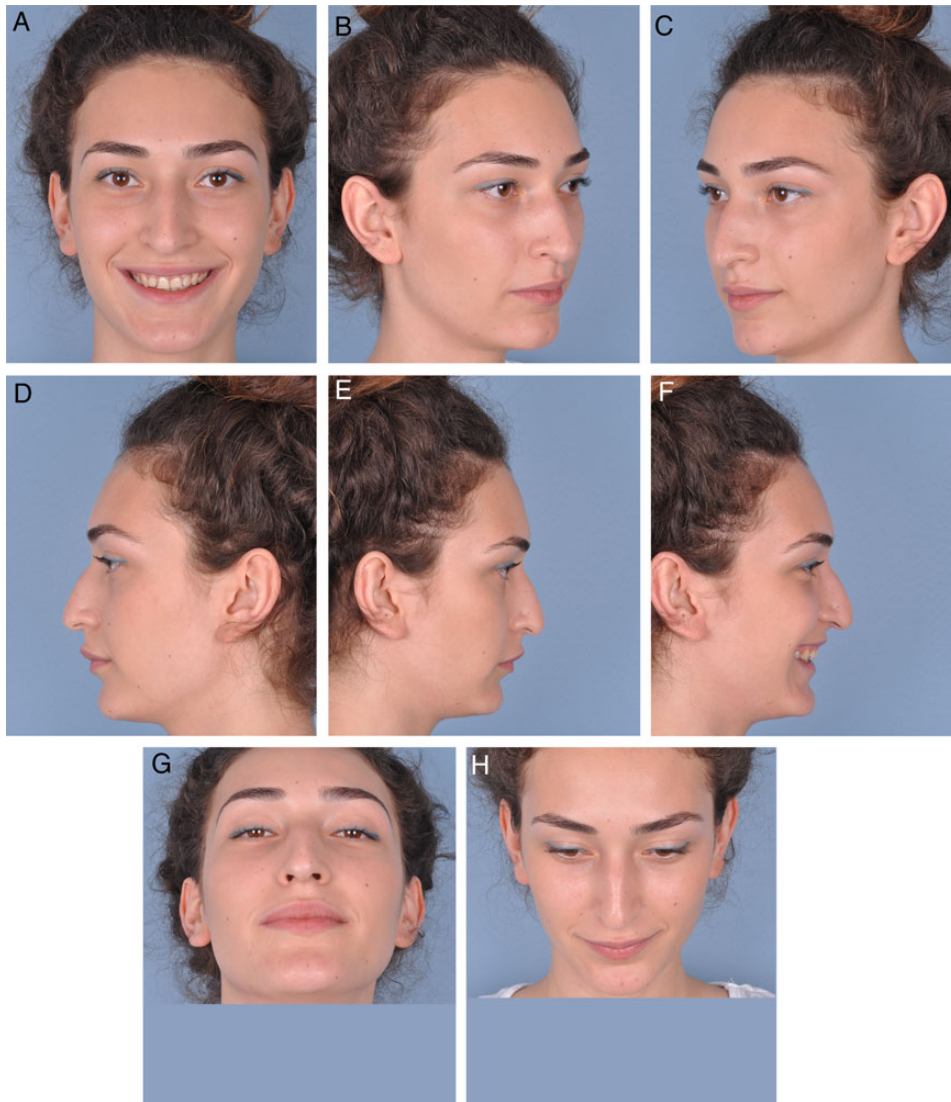

Figure 7. (A, G, H) Frontal, (B, C) oblique, and (D-F) profile preoperative photographs of this 25-year-old woman (also presented in Figures 3, 4, and 6) who underwent ultrasonic osteotomy.

that were similar in terms of age distribution and gender ratio. However, 16 patients were unavailable for follow-up and in order to arrange sex and age range of the groups, 4 patients were dismissed from the study. Ultimately, the ultrasonic osteotomy group comprised 34 patients, and the conventional osteotomy group comprised 22 patients. Although fewer patients were included in the study than originally planned, the number of patients in each group remained large enough for sufficient statistical power.

Of the 56 patients who underwent rhinoplasty and were evaluated prospectively, 48 (85.7%) were women and 8 (14.3%) were men. The mean age of the patients was 26.07 years (standard deviation [SD], 6.48 years; range, 20-52 years). The distributions of scores given by each examiner

for edema and ecchymosis on postoperative days 3 and 7 are presented in Table 1 and in Figures 11 and 12.

Ecchymosis scores on postoperative day 3 were significantly higher for patients who underwent conventional osteotomy (2.50 ± 0.74 and 2.55 ± 0.80 as determined by examiners 1 and 2, respectively) than for patients who underwent ultrasonic osteotomy (1.50 ± 1.11 and 1.59 ± 1.08 , respectively; $P = .001$ for both examiners; Table 2). Similarly, ecchymosis scores on postoperative day 7 were higher for patients who underwent conventional osteotomy (1.14 ± 0.64 and 0.91 ± 0.97 , respectively) than for patients who underwent ultrasonic osteotomy (0.32 ± 0.64 and 0.32 ± 0.59 , respectively; $P = .001$ [examiner 1] and $P = .01$ [examiner 2]; Table 2). Ecchymosis scores decreased from day 3 to day 7 for patients in both surgical groups, as scored by

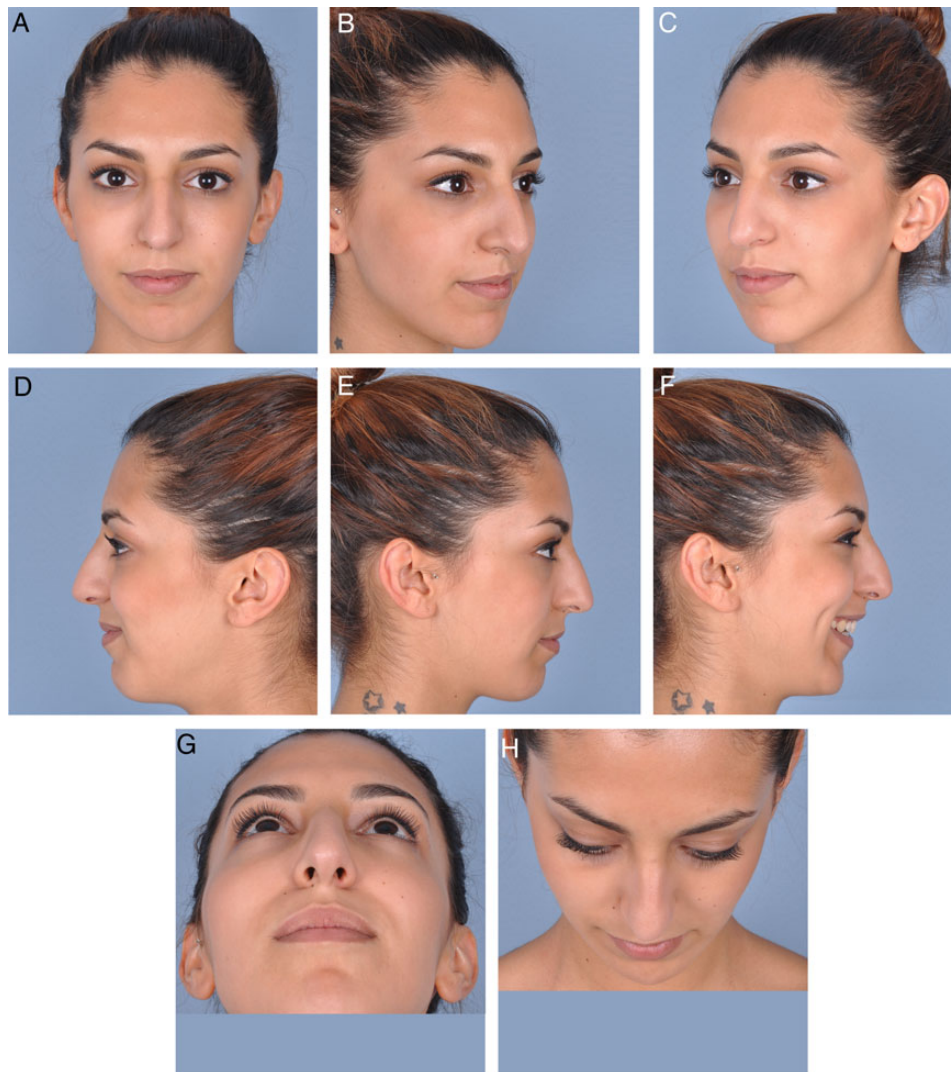


Figure 8. (A, G, H) Frontal, (B, C) oblique, and (D-F) profile preoperative photographs of this 23-year-old woman (also presented in Figure 5) who underwent conventional osteotomy.

both examiners ($P = .001$ for both). The extents of the decreases in ecchymosis scores for patients who underwent conventional vs ultrasonic osteotomy were similar ($P > .05$; Table 2).

Edema scores on postoperative day 3 were significantly higher in the group of patients who underwent conventional osteotomy (1.91 ± 0.81 and 1.68 ± 1.04 , as determined by examiners 1 and 2, respectively) than in the ultrasonic osteotomy group (1.15 ± 0.78 and 0.91 ± 0.87 , respectively; $P = .002$ [examiner 1] and $P = .007$ [examiner 2]; Table 3). Edema scores on postoperative day 7 were significantly higher in the conventional osteotomy group than in the ultrasonic osteotomy group, as determined by examiner 1 (1.09 ± 0.53 for conventional vs 0.26 ± 0.45 for ultrasonic; $P = .001$). However examiner 2 did not score the groups significantly differently from day 3 to day 7 (0.36 ± 0.58 vs 0.12 ± 0.33 , respectively; $P = .061$).

Examiner 1 indicated similar improvements in edema for the 2 surgical techniques from day 3 to day 7 ($P > .05$). Examiner 2 indicated greater improvement from day 3 to day 7 among patients who underwent conventional osteotomy vs ultrasonic osteotomy ($P = .017$). Edema scores are summarized in Table 3.

In 1 patient who underwent ultrasonic osteotomy, an invaded maxillary sinus developed from the medial wall. This complication required no intervention. No other complications were recorded in either patient group.

DISCUSSION

For successful rhinoplasty, the surgeon must sculpt the bony pyramid while preserving the soft-tissue envelope. Surgical maneuvers to shape the bony structure of the nose typically are challenging and associated with complications.¹³ For

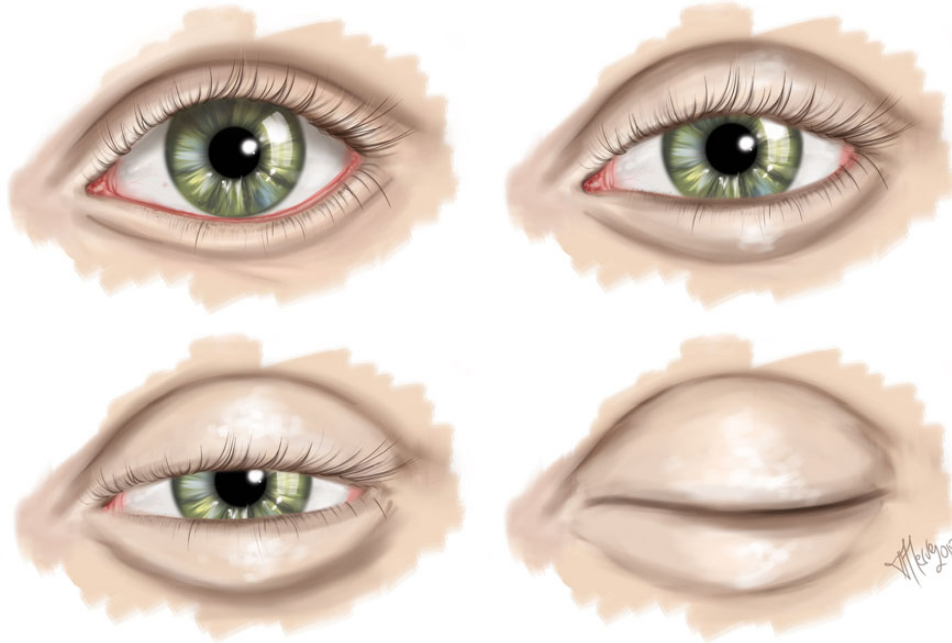


Figure 9. Schematic guide for scoring edema as applied in this study. Top left image depicts no coverage of iris with eyelids (grade 1). Top right depicts slight coverage of iris with swollen eyelids (grade 2). Bottom left depicts full coverage of iris with swollen eyelids (grade 3). Bottom right depicts full closure of eyes (grade 4).

osteotomy, the surgeon must perform a series of procedures that may include decreasing dead space, narrowing the lateral walls of the nose, reducing the dorsal hump, closing an open-roof deformity, and straightening the bony framework of the nose to create symmetry.^{14,15}

Many studies have addressed osteotomy techniques and instruments.^{3,16-18} In a cadaver study, Kuran et al¹⁹ determined the average thickness of osteotomized segments of the nasal pyramid and found that lateral-wall thickness correlated with fragmentation rate and soft-tissue injury in lateral osteotomy. In a subsequent cadaver study, Harshbarger and Sullivan²⁰ confirmed these results. Kuran et al¹⁹ also compared different types of osteotomes and concluded that a narrow, curved chisel was optimal to minimize soft-tissue injury. Becker et al²¹ described a power-assisted technique to address the nasal dorsum that resulted in less tissue disruption than observed with rasping. Sinha et al²² compared external osteotomy with internal osteotomy and found that external osteotomy caused less edema and ecchymosis. Therefore, our choice of internal osteotomy may be considered a limitation of our study. In addition, Nolst Trenité²³ described the utility of micro-osteotomes to reduce postoperative ecchymosis and edema when refining the bony pyramid of the nose. In the present study, we performed conventional osteotomy with a 4-mm curved osteotome, which is not considered delicate and is known to produce substantial ecchymosis and edema.^{2,20}

It is difficult to evaluate the quality of an osteotomy instrument in isolation because the instrument must be

applied to an operation that is highly dependent on the ability and experience of the surgeon. The effectiveness of osteotomy instrumentation has been described in terms of intraoperative bleeding and postoperative complications such as edema and ecchymosis, which result from soft-tissue injury.^{1,12} When performing osteotomy, it is important to avoid narrowing the nasal passage and to prevent a step deformity or bony deformity on the osteotomy line.⁵ By applying a piezosurgical device that selectively sections hard and soft tissues, we were able to avoid tearing the inner mucosa and inducing intraoperative and early postoperative bleeding. Additional studies are warranted to verify these observations.

A few authors have compared osteotomy techniques in terms of edema and ecchymosis postoperatively. Yucel¹³ evaluated intranasal osteotomy and percutaneous (or external) osteotomy and found that ecchymosis in the external osteotomy group on the second postoperative day was substantial and significantly greater than that of the intranasal osteotomy group. Similarly, Kara and Gökalan¹² found that ecchymosis reached a peak level on the second day after rhinoplasty. We chose to evaluate ecchymosis and edema on the third postoperative day to capture peak levels of these outcomes rather than rising levels.

Osteotomy with conventional osteotomes is associated with mucosal injury and trauma to overlying soft tissue that can lead to bleeding, bruising, and edema.^{24,25} Lateral



Figure 10. Schematic guide for scoring ecchymosis as applied in this study. Ecchymosis extending to the medial one-third of the lower and/or upper eyelid corresponded to grade 1. Ecchymosis extending to the medial two-thirds of the lower and/or upper eyelid corresponded to grade 2. Ecchymosis extending the full length of the lower and/or upper eyelid corresponded to grade 3.

osteotomy can cause bleeding into the soft tissue owing to disruption of the angular artery or vein. Edema and ecchymosis develop perioperatively and may persist until the ninth postoperative day.¹⁵ Periorbital ecchymosis and edema may be exacerbated by vigorous rasping and the application of a large osteotome.²⁶ Eyelid edema and periorbital ecchymosis may develop postoperatively and cause great concern in patients. Palpebral edema can affect vision, and periorbital ecchymosis is socially off-putting and may result in increased pigmentation.^{27,28}

We believe that the primary limitations of conventional osteotomy are blind manipulation and insufficient surgical experience.^{26,29,30} Therefore, our objective was to identify the optimal combination of surgical technique and instrumentation that would reduce the likelihood and severity of complications and minimize the impact of the surgeon's experience. In an observational study, Robiony et al⁹ utilized piezosurgery to perform osteotomy and demonstrated that this technique was associated with minimal amounts of bleeding, edema, and periorbital ecchymosis. However,

Table 1. Distribution of Ecchymosis and Edema Scores by Examiner

Score	Postoperative Day 3				Postoperative Day 7			
	Examiner 1		Examiner 2		Examiner 1		Examiner 2	
	CNV	ULT	CNV	ULT	CNV	ULT	CNV	ULT
Ecchymosis								
0	0 (0)	8 (23.5)	0 (0)	7 (20.6)	3 (13.6)	26 (76.5)	9 (40.9)	25 (73.5)
1	3 (13.6)	9 (26.5)	4 (18.2)	8 (23.5)	13 (59.1)	5 (14.7)	8 (36.4)	7 (20.6)
2	5 (22.7)	9 (26.5)	2 (9.1)	11 (32.4)	6 (27.3)	3 (8.8)	3 (13.6)	2 (5.9)
3	14 (63.6)	8 (23.5)	16 (72.7)	8 (23.5)	0 (0)	0 (0)	2 (9.1)	0 (0)
Edema								
0	0 (0)	7 (20.6)	3 (13.6)	13 (38.2)	2 (9.1)	25 (73.5)	15 (68.2)	30 (88.2)
1	8 (36.4)	16 (47.1)	7 (31.8)	12 (35.3)	16 (72.7)	9 (26.5)	6 (27.3)	4 (11.8)
2	8 (36.4)	10 (29.4)	6 (27.3)	8 (23.5)	4 (18.2)	0 (0)	1 (4.5)	0 (0)
3	6 (27.3)	1 (2.9)	6 (27.3)	1 (2.9)	0 (0)	0 (0)	0 (0)	0 (0)

Values represent no. (%) of patients who received each score. Scoring system was based on those of Kara et al²³ and Yucel.¹² CNV, conventional osteotomy (n = 22); ULT, ultrasonic osteotomy (n = 34).

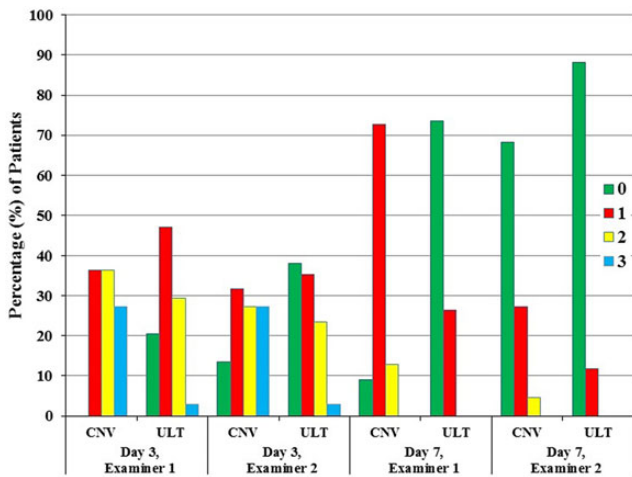


Figure 11. Distribution of edema scores by surgical technique (CNV, conventional osteotomy; ULT, ultrasonic osteotomy) by postoperative day (3 or 7) and by examiner (1 or 2).

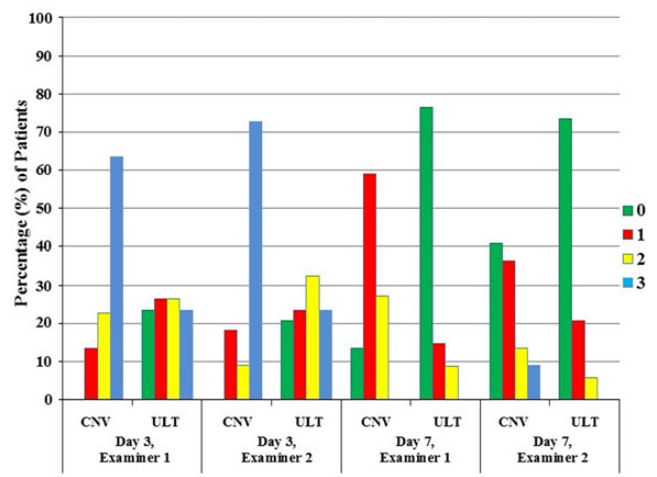


Figure 12. Distribution of ecchymosis scores by surgical technique (CNV, conventional osteotomy; ULT, ultrasonic osteotomy) by postoperative day (3 or 7) and by examiner (1 or 2).

these authors did not compare piezosurgery with other osteotomy techniques. Pribitkin et al¹¹ performed sculpting of the nasal dorsum with an ultrasonic bone aspirator and noted that the technique was safe and precise. However, this study was observational, not comparative. In a study set in an academic clinic for facial plastic surgery, Greywoode and Pribitkin³⁰ applied an ultrasonic bone aspirator to reduce the nasal spine, deepen the glabella, sculpt mobile

bone fragments and smooth bony edges after medial osteotomy, and reduce the convexity of the nasal bones. These authors described the aesthetic results of this procedure in terms of subjective evaluations by the patients and surgeon, and they did not compare this approach to conventional osteotomy.³⁰ In a cadaver study, Ghassemi et al³¹ performed osteotomy with a piezo scalpel and found it to be effective, as assessed histologically.

Table 2. Descriptive Statistics of Ecchymosis Scores by Examiner

		Examiner 1		P Value ^a	Examiner 2		P Value ^a
		CNV	ULT		CNV	ULT	
Day 3	Min-max (median)	1-3 (3)	0-3 (1.5)	.001	1-3 (3)	0-3 (2)	.001
	Mean ± SD	2.50 ± 0.74	1.50 ± 1.11		2.55 ± 0.80	1.59 ± 1.08	
Day 7	Min-max (median)	0-2 (1)	0-2 (0)	.001	0-3 (1)	0-2 (0)	.010
	Mean ± SD	1.14 ± 0.64	0.32 ± 0.64		0.91 ± 0.97	0.32 ± 0.59	
	P value ^b	.001	.001		.001	.001	
Day 3-7, difference	Min-max (median)	0-3 (1)	0-3 (1)	.457	0-3 (2)	0-3 (1)	.151
	Mean ± SD	1.36 ± 0.66	1.18 ± 0.83		1.64 ± 0.90	1.26 ± 0.86	

CNV, conventional osteotomy (n = 22); Max, maximum; Min, minimum; SD, standard deviation; ULT, ultrasonic osteotomy (n = 34). ^aMann-Whitney U test, ^bWilcoxon signed-rank test.

Table 3. Descriptive Statistics of Edema Scores by Examiner

		Examiner 1		P Value ^a	Examiner 2		P Value ^a
		CNV	ULT		CNV	ULT	
Day 3	Min-max (median)	1-3 (2)	0-3 (1)	.002	0-3 (2)	0-3 (1)	.007
	Mean ± SD	1.91 ± 0.81	1.15 ± 0.78		1.68 ± 1.04	0.91 ± 0.87	
Day 7	Min-max (median)	0-2 (1)	0-1 (0)	.001	0-2 (0)	0-1 (0)	.061
	Mean ± SD	1.09 ± 0.53	0.26 ± 0.45		0.36 ± 0.58	0.12 ± 0.33	
	P value ^b	.001	.001		.001	.001	
Day 3-7, difference	Min-max (median)	0-2 (1)	0-2 (1)	.692	0-3 (1)	0-2 (1)	.017
	Mean ± SD	0.82 ± 0.59	0.88 ± 0.59		1.32 ± 0.78	0.79 ± 0.73	

CNV, conventional osteotomy (n = 22); Max, maximum; Min, minimum; SD, standard deviation; ULT, ultrasonic osteotomy (n = 34). ^aMann-Whitney U test, ^bWilcoxon signed-rank test.

In the present comparative study, we found the piezosurgical device to be safe and effective. Patients in our study who underwent ultrasonic osteotomy experienced less edema and ecchymosis compared with patients who underwent osteotomy with a conventional osteotome. Moreover, no patient in the ultrasonic osteotomy group experienced complications or required revisions. Nevertheless, the ultrasonic approach involved a learning curve, and the piezosurgical device and handpieces were costly. The soft tissues must be elevated, and assistance was needed for aspiration intraoperatively. Direct lateral visualization and wide elevation were difficult, especially in patients with low skin elasticity. The examiners in this study scored edema and ecchymosis from photographs to ensure blinding to the osteotomy procedure. However, this approach constitutes a limitation of our study because it is challenging to precisely score edema and ecchymosis from photographs alone.

Batniji and Gerbault³² described the elevation of soft tissue of the lateral nasal wall with extended periosteal

dissection for complete visualization during osteotomy. Similarly, we elevated the soft tissue enveloping the lateral nasal wall to enable direct visualization during lateral osteotomy. Patients who underwent ultrasonic osteotomy received extensive undermining to fully expose the nasal bones and facilitate direct visualization. Patients who underwent conventional osteotomy received less undermining, and corresponding surgical maneuvers were performed blindly. This difference in the extent of undermining may constitute a limitation of our study, but limited undermining is a feature of conventional osteotomy.

CONCLUSIONS

Several surgical modifications to osteotomy have been described. The ideal osteotomy technique should be safe and easy to perform, should allow for accurate and precise control, and should yield a pleasing aesthetic result. The results of this comparative study suggest that ultrasonic

osteotomy is safe, effective, and precise and is associated with decreased severities of edema and ecchymosis, compared with conventional osteotomy. These findings support the results of other studies in which authors applied piezosurgery to rhinoplasty.^{30,31} The present study assessed edema and ecchymosis at 3 and 7 days postoperatively. Subsequent studies are needed to evaluate long-term aesthetic results and patient satisfaction with ultrasonic osteotomy.

Supplementary Material

This article contains supplementary material located online at www.aestheticsurgeryjournal.com.

Disclosures

The authors declared no potential conflicts of interest with respect to the research, authorship, and publication of this article.

Funding

The authors received no financial support for the research, authorship, and publication of this article.

REFERENCES

- Hilger JA. The internal lateral osteotomy in rhinoplasty. *Arch Otolaryngol*. 1968;88(2):211-212.
- Goldfarb M, Gallups JM, Gerwin JM. Perforating osteotomies in rhinoplasty. *Arch Otolaryngol Head Neck Surg*. 1993;119(6):624-627.
- Becker DG, McLaughlin RB Jr, Loevner LA, Mang A. The lateral osteotomy in rhinoplasty: clinical and radiographic rationale for osteotome selection. *Plast Reconstr Surg*. 2000; 105(5):1806-1816, discussion 1817-1819.
- Gryskiewicz JM, Gryskiewicz KM. Nasal osteotomies: a clinical comparison of the perforating methods versus the continuous technique. *Plast Reconstr Surg*. 2004; 113(5):1445-1456, discussion 1457-1458.
- Ford CN, Battaglia DG, Gentry LR. Preservation of periosteal attachment in lateral osteotomy. *Ann Plast Surg*. 1984;13(2):107-111.
- Erişir F, Tahamiler R. Lateral osteotomies in rhinoplasty: a safer and less traumatic method. *Aesthet Surg J*. 2008;28(5):518-520.
- Horton JE, Tarpley TM Jr, Wood LD. The healing of surgical defects in alveolar bone produced with ultrasonic instrumentation, chisel, and rotary bur. *Oral Surg Oral Med Oral Pathol*. 1975;39(4):536-546.
- Horton JE, Tarpley TM Jr, Jacoway JR. Clinical applications of ultrasonic instrumentation in the surgical removal of bone. *Oral Surg Oral Med Oral Pathol*. 1981;51(3):236-242.
- Robiony M, Polini F, Costa F, Vercellotti T, Politi M. Piezoelectric bone cutting in multipiece maxillary osteotomies. *J Oral Maxillofac Surg*. 2004;62(6):759-761.
- Robiony M, Toro C, Costa F, Sembronio S, Polini F, Politi M. Piezosurgery: a new method for osteotomies in rhinoplasty. *J Craniofac Surg*. 2007;18(5):1098-1100.
- Pribitkin EA, Lavasani LS, Shindle C, Greywoode JD. Sonic rhinoplasty: sculpting the nasal dorsum with the ultrasonic bone aspirator. *Laryngoscope*. 2010;120(8):1504-1507.
- Kara CO, Gökalan I. Effects of single-dose steroid usage on edema, ecchymosis, and intraoperative bleeding in rhinoplasty. *Plast Reconstr Surg*. 1999;104(7):2213-2218.
- Yücel OT. Which type of osteotomy for edema and ecchymosis: external or internal? *Ann Plast Surg*. 2005;55(6):587-590.
- Thomas JR, Griner NR, Remmler DJ. Steps for a safer method of osteotomies in rhinoplasty. *Laryngoscope*. 1987;97(6):746-747.
- Parkes ML, Kamer F, Morgan WR. Double lateral osteotomy in rhinoplasty. *Arch Otolaryngol*. 1977;103(6):344-348.
- Castro A, Jackson IT, Rademaker B. Rhinoplasty saw: a modified design. *Ann Plast Surg*. 1991;26(6):600-601.
- Farrion RT. The osteotomy in rhinoplasty. *Laryngoscope*. 1978;88(9 Pt 1):1449-1459.
- Webster RC, Davidson TM, Smith RC. Curved lateral osteotomy for airway protection in rhinoplasty. *Arch Otolaryngol*. 1977;103(8):454-458.
- Kuran I, Ozcan H, Usta A, Bas L. Comparison of four different types of osteotomes for lateral osteotomy: a cadaver study. *Aesthetic Plast Surg*. 1996;20(4):323-326.
- Harshbarger RJ, Sullivan PK. Lateral nasal osteotomies: implications of bony thickness on fracture patterns. *Ann Plast Surg*. 1999;42(4):365-370, discussion 370-371.
- Becker DG, Toriumi DM, Gross CW, Tardy ME Jr. Powered instrumentation for dorsal reduction. *Facial Plast Surg*. 1997;13(4):291-297.
- Sinha V, Gupta D, More Y, Prajapati B, Kedia BK, Singh SN. External vs. internal osteotomy in rhinoplasty. *Indian J Otolaryngol Head Neck Surg*. 2007;59(1):9-12.
- Nolst Trenité GJ. Trauma reduction in rhinoplastic surgery. *Rhinology*. 1991; 29(2):111-116.
- Rohrich RJ, Krueger JK, Adams WP Jr, Hollier LH Jr. Achieving consistency in the lateral nasal osteotomy during rhinoplasty: an external perforated technique. *Plast Reconstr Surg*. 2001; 108(7):2122-2130, discussion 2131-2132.
- Cochran CS, Ducic Y, Defatta RJ. Rethinking nasal osteotomies: an anatomic approach. *Laryngoscope*. 2007;117(4):662-667.
- Hoffmann DF, Cook TA, Quatela VC, Wang TD, Brownrigg PJ, Brummett RE. Steroids and rhinoplasty. A double-blind study. *Arch Otolaryngol Head Neck Surg*. 1991;117(9):990-993, discussion 994.
- Kuflik EG, Webb W. Effects of systemic corticosteroids on post-cryosurgical edema and other manifestations of the inflammatory response. *J Dermatol Surg Oncol*. 1985;11(5):464-468.
- Rohrich RJ, Janis JE, Adams WP, Krueger JK. An update on the lateral nasal osteotomy in rhinoplasty: an anatomic endoscopic comparison of the external versus the internal approach. *Plast Reconstr Surg*. 2003;111(7):2461-2462, discussion 2463.

29. Kim JT, Kim SK. Endoscopically assisted, intraorally approached corrective rhinoplasty. *Plast Reconstr Surg*. 2001;108(1):199-205, discussion 206-207.
30. Greywoode JD, Pribitkin EA. Sonic rhinoplasty: histologic correlates and technical refinements using the ultrasonic bone aspirator. *Arch Facial Plast Surg*. 2011; 13(5):316-321.
31. Ghassemi A, Prescher A, Talebzadeh M, Hölzle F, Modabber A. Osteotomy of the nasal wall using a newly designed piezo scalpel--a cadaver study. *J Oral Maxillofac Surg*. 2013;71(12):2155.e1-6.
32. Gerbault O, Daniel RK, Kosins AM. The Role of Piezoelectric Instrumentation in Rhinoplasty Surgery. *Aesthet Surg J*. 2016; 36(1):21-34.